



The Others:

Peculiar Headache and Facial Pain Syndromes

JUSTIN S. MOON, M.D., M.P.H.

HEADACHE AND FACIAL PAIN SPECIALIST

DENVER NEUROLOGICAL CLINIC

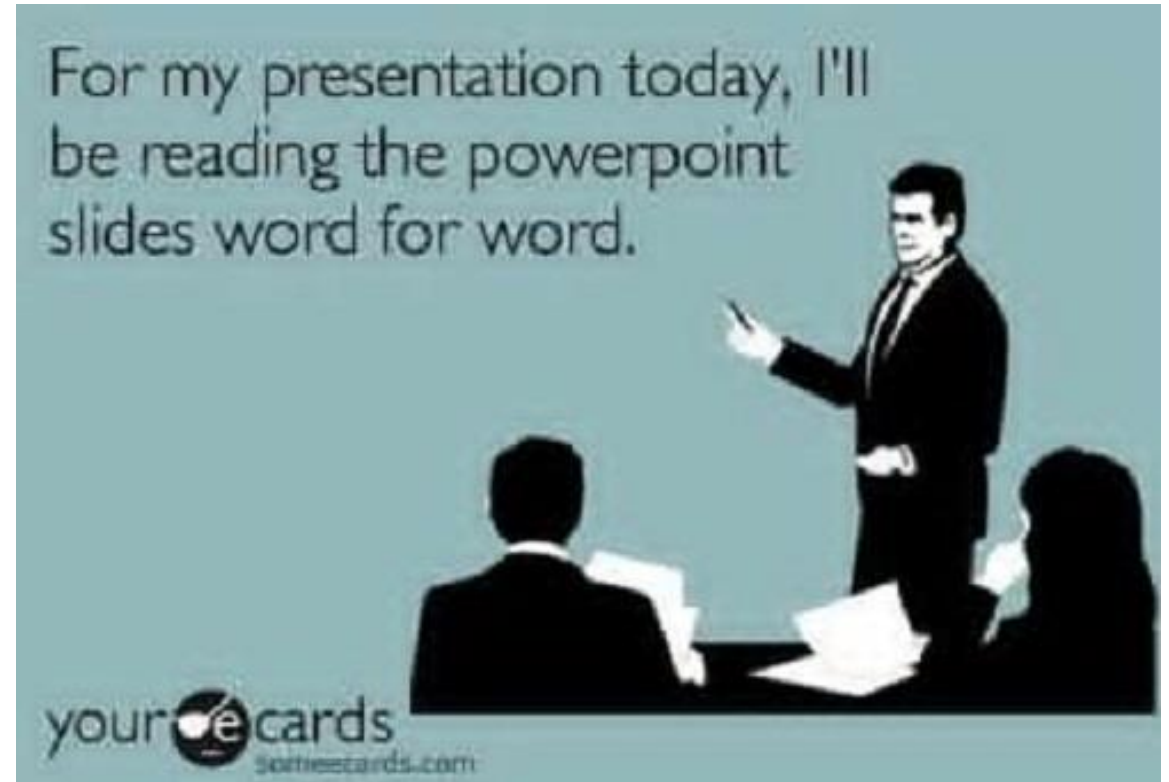
APRIL 15, 2019

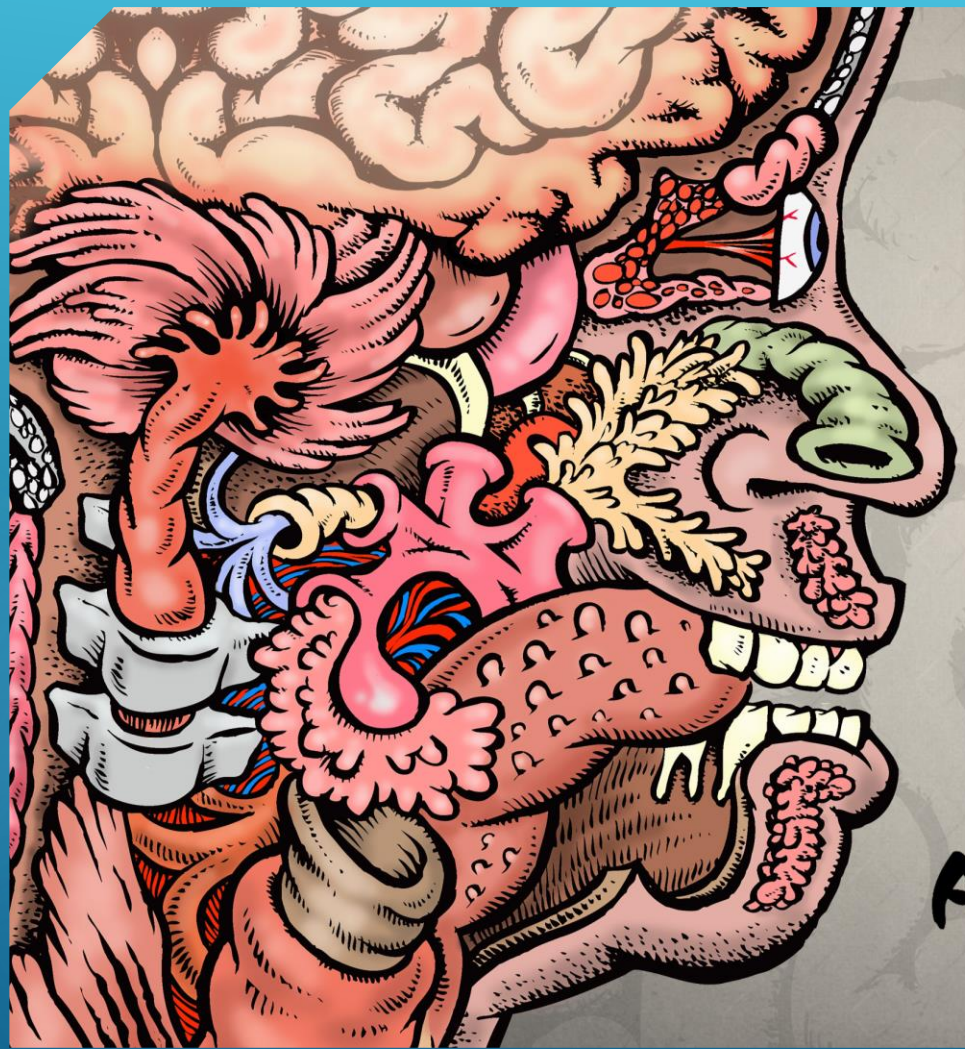
Disclosures

- ▶ None related to the talk

Objectives

- ▶ Review less common pain syndromes of the head and face
- ▶ Discuss new insights into pathophysiology
- ▶ Considerations for clinical decision making and treatment

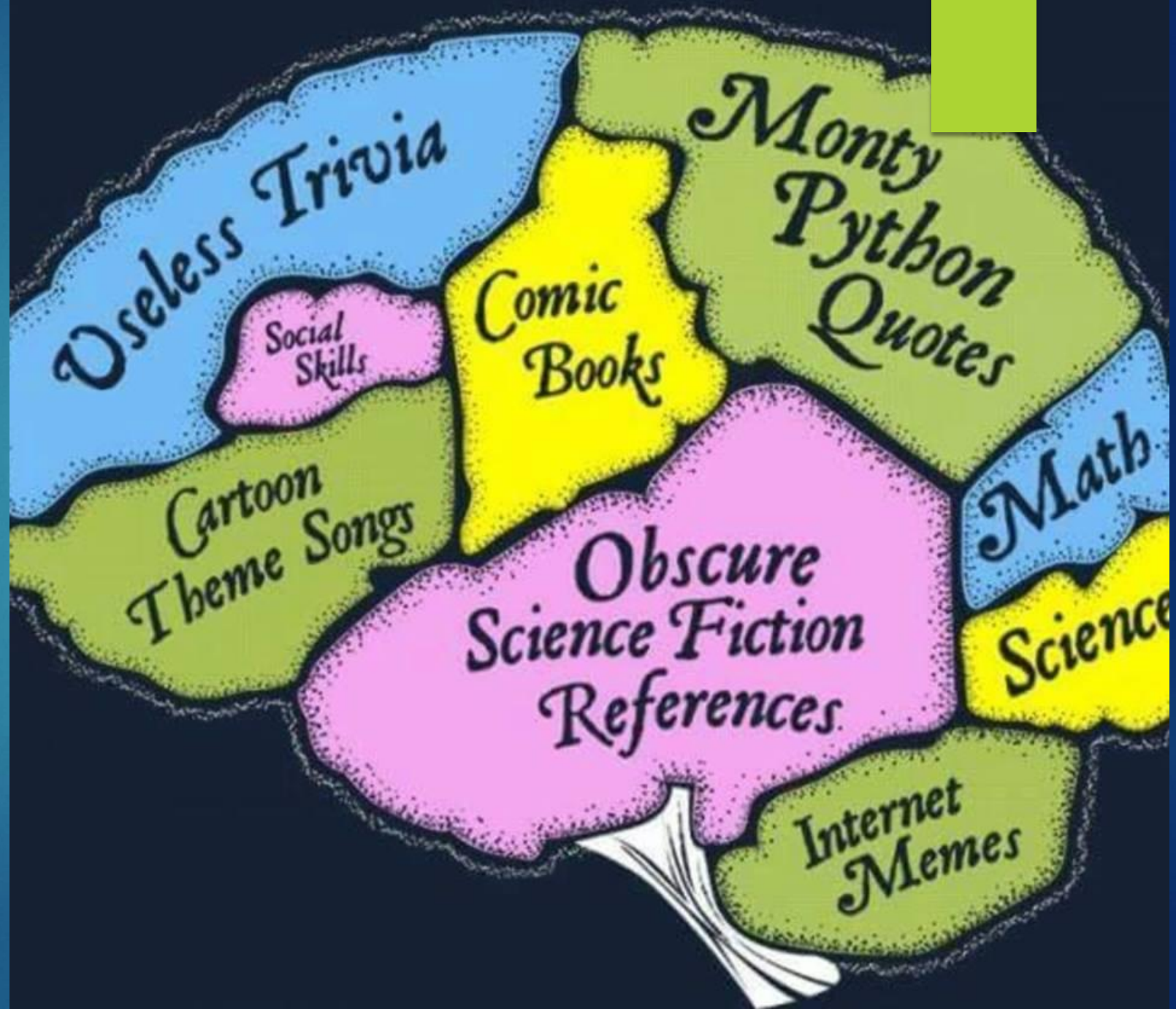




THE MIND^{of} a CHEF

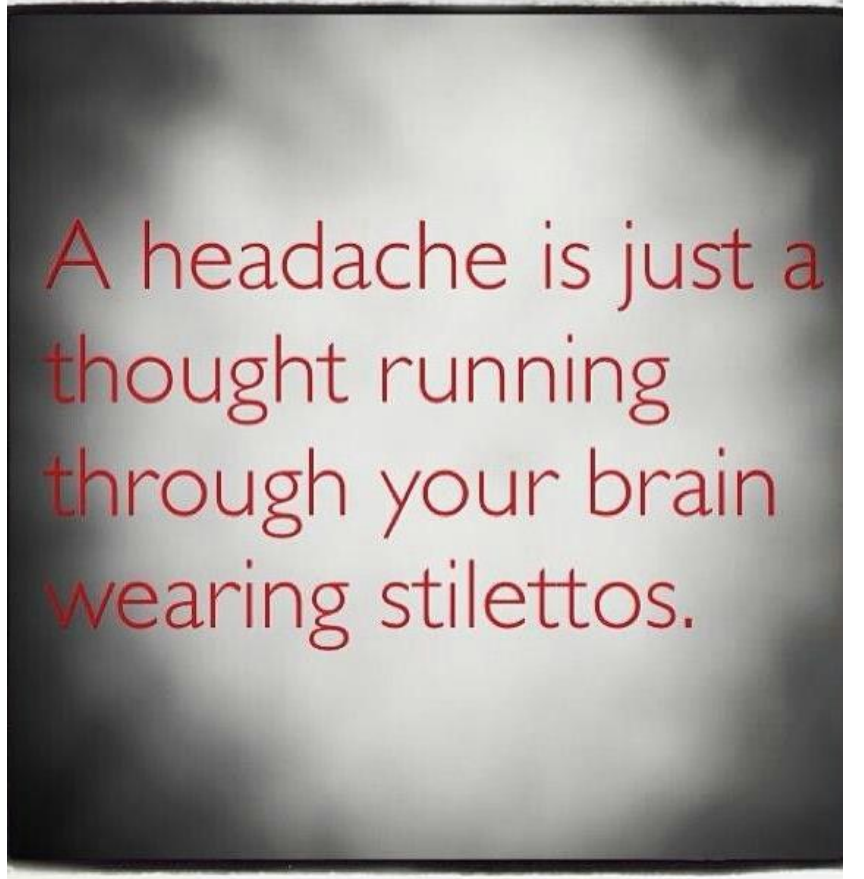
NARRATED BY
ANTHONY BOURDAIN

Mind of a Neurologist



62 yo man with “trigeminal neuralgia”

- ▶ Patient with bouts of stabbing pain in the left eye 40 times per day
- ▶ Ptosis, red eye, tearing are noted
- ▶ Wakes him up in the middle of the night
- ▶ Prior microvascular decompression and gamma knife

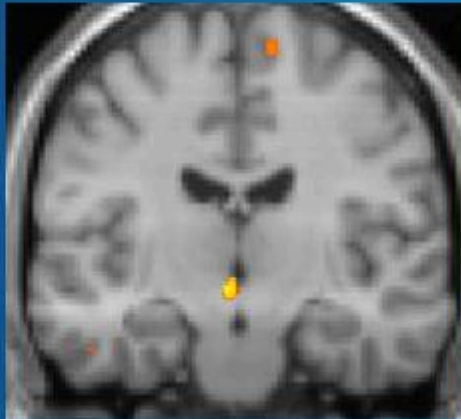A rectangular area with a dark, blurry background. Overlaid on this background is text in a red, serif font. The text is arranged in four lines, reading: "A headache is just a thought running through your brain wearing stilettos." Above this rectangular area, in the top right corner of the slide, is a small, solid green rectangle.

A headache is just a thought running through your brain wearing stilettos.

Trigeminal Autonomic Cephalalgias

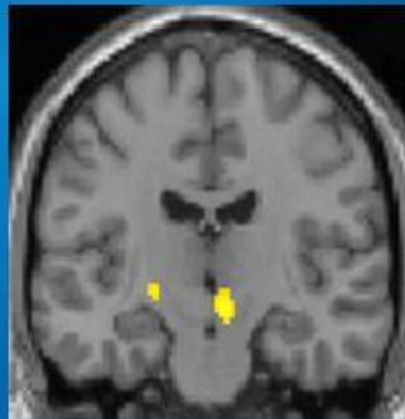EVIDENCE FOR HYPOTHALAMIC DYSFUNCTION

Cluster Headache
PET Study



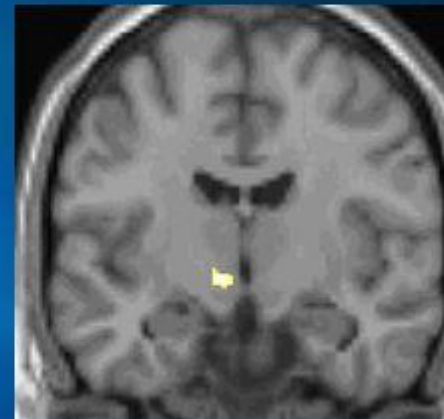
May *et al*, Lancet 1998

Paroxysmal Hemicrania
PET Study



Matharu *et al*, Ann Neurol 2004

SUNCT
fMRI Study



May *et al*, Ann Neurol 1999

Posterior hypothalamic region activation in all trigeminal autonomic cephalalgias

Treatments

Cluster

Verapamil
Melatonin
Steroids
Lithium

Paroxysmal Hemicrania

Indomethacin
Verapamil
Steroids

SUNCT

Lamotrigine
Carbamezapine
Steroids
Gabapentin

15 year old girl with movement and pain

- ▶ Mother describes 6 months of occasional contortion of the head in a very repetitive pattern to the left being stuck for 3-5 minutes with a flexing posture of the arms.
- ▶ Patient does not feel it is voluntary and cannot stop the maneuver.
- ▶ Episodes are followed by a low grade headache lasting 2hrs to 12hrs and light sensitivity and irritability



"This is Gils del la Tourettes Syndrome...or she is crazy."

-Martha Stewart, M.D. Connecticut



"Supplementary Motor Cortex seizure disorder in the context of migralepsy...or she is nuts."

-Bob Abdul-Jabbar, D.O. Los Angeles



"Psychosomatic...that is when you can start fire from your thoughts."

-Mike Honcho, M.D. Harvard

Benign paroxysmal torticollis (a migraine syndrome)

- ▶ Migraine
- ▶ Dystonic spell lasting minutes to days
- ▶ One of the following:
 - ▶ 1. pallor 2. irritability 3. malaise 4. vomiting 5. ataxia

Topiramate

- ▶ Fixed migraine
- ▶ Fixed movement
- ▶ Did not fix irritability

45 yo woman who comes in for pain and redness of the face and neck

- ▶ Pain is a burning and stabbing pain in the forehead, cheek, ears, and anterior neck associated with diaphoresis.
- ▶ There is a redness of the face down the middle of the face and anterior neck stopping at the base of the neck extending to the ears on the left side.
- ▶ Episodes last 45 minutes and are exacerbated with alcohol.

Evaluation

- ▶ Exam is normal including sensation of the face
- ▶ MRI brain and MRI soft tissue neck normal
- ▶ CXR normal
- ▶ Labs including HSV and VZV unremarkable

“She must be only half Asian with that enzyme thing”

Harlequin Syndrome




“URGENT ADD ON” 38 yo man with headache during sex

- ▶ Central deep, sharp pain lasting 2 hours during climax with partner...or without partner
- ▶ No associated symptoms
- ▶ MRI Brain negative
- ▶ Lots of tears involved

What do you do next?

- ▶ MRA
- ▶ Start Indomethacin 30 minutes before sexual activity
- ▶ Stop using performance enhancing drugs



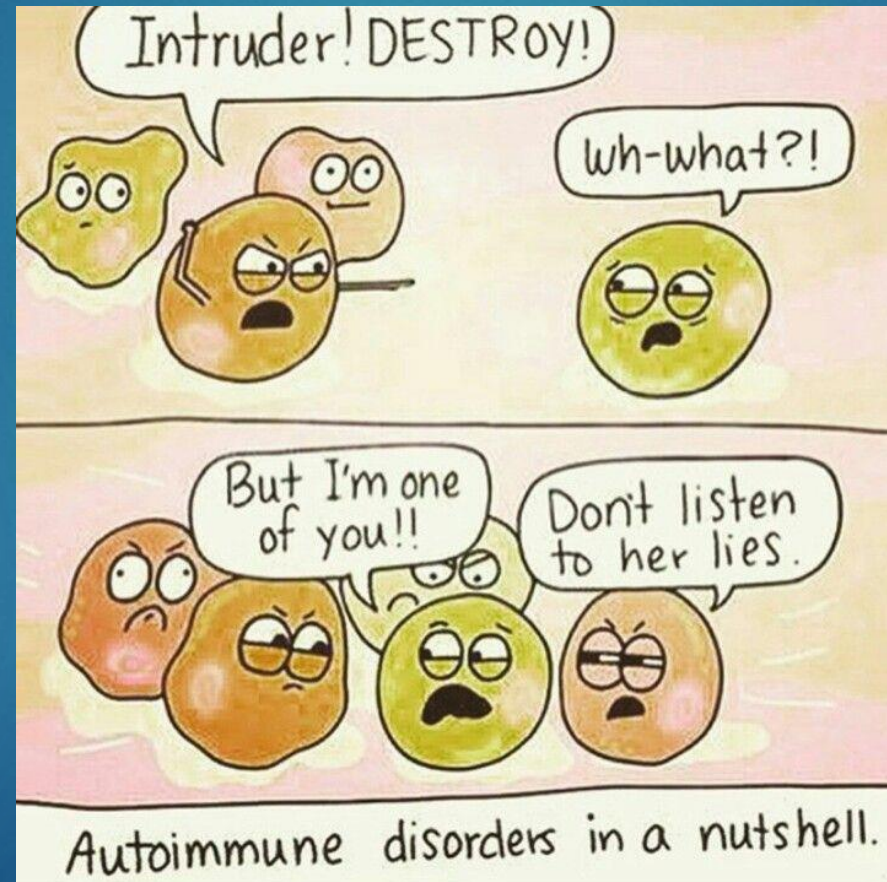
54 yo man with two spells of headache and tingling

- ▶ No prior history of headaches with new throbbing pain on the left lasting several hours
- ▶ Nausea and photophobia
- ▶ Right hand and right foot tingling on the tips lasting 20 minutes
- ▶ No facial involvement

Work up

- ▶ MRI/MRA head and neck negative
- ▶ ECHO negative
- ▶ Started on ASA
- ▶ But...peculiar

Antiphospholipid syndrome



26 yo hockey player with headaches after a hit

- ▶ Patient blindsided in a game
- ▶ Altered consciousness immediately
- ▶ Out of action for nearly 1.5 years
- ▶ Throbbing headache, photosensitivity, worsened with activity

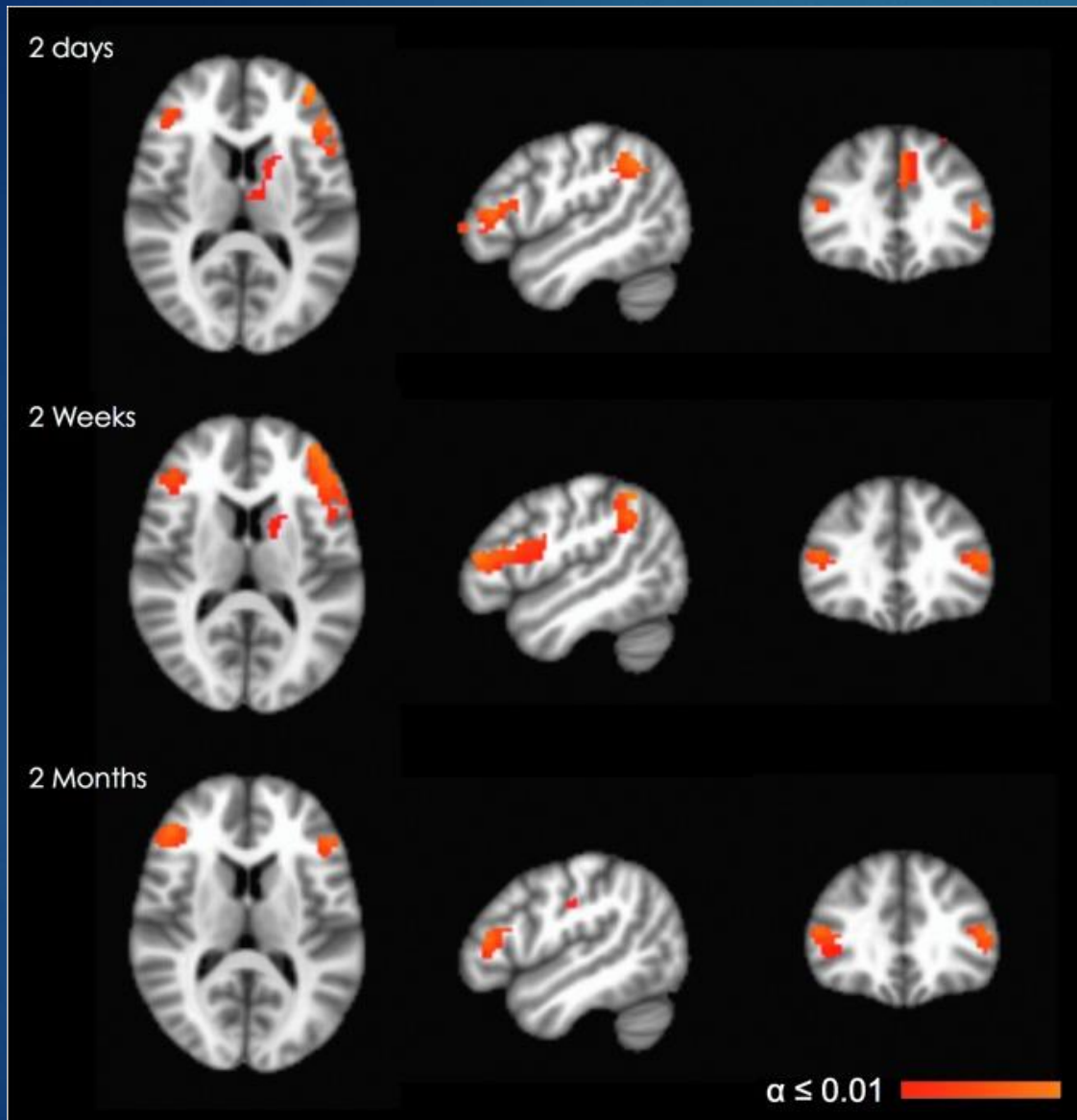
Diagnosis and Treatment

- ▶ Post traumatic chronic migraine
- ▶ D.H.E. inpatient protocol
- ▶ Verapamil ER 120mg
- ▶ Another victory for neurology

Persistent Differences in Patterns of Brain Activation after Sports-Related Concussion: A Longitudinal Functional Magnetic Resonance Imaging Study

[Annegret Dettwiler](#), ¹ [Murali Murugavel](#), ¹ [Margot Putukian](#), [Valerie Cubon](#), ³ [John Furtado](#), ² and [Daniel Osherson](#) ⁴

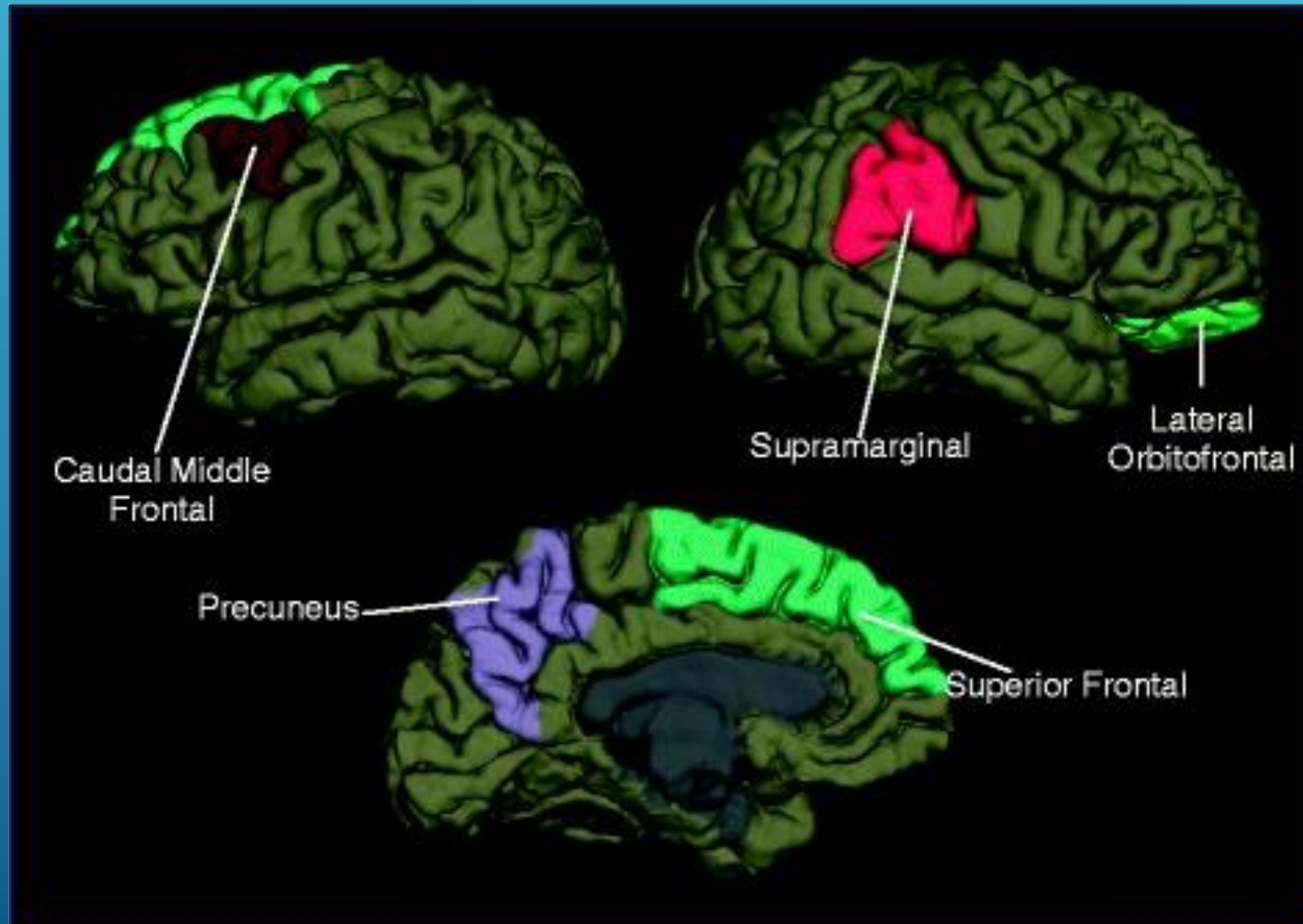
- 15 students
- Asymptomatic 2 weeks
- Normal working memory test
- Return to play 9-31 days except 4



- ▶ Posterior lateral frontal cortex
- ▶ Parietal lobe

Persistent post-traumatic headache vs.
migraine: an MRI study demonstrating
differences in brain structure

Todd J. Schwedt, Catherine D. Chong, Jacob Peplinski, Katherine Ross, and Visar
Berisha



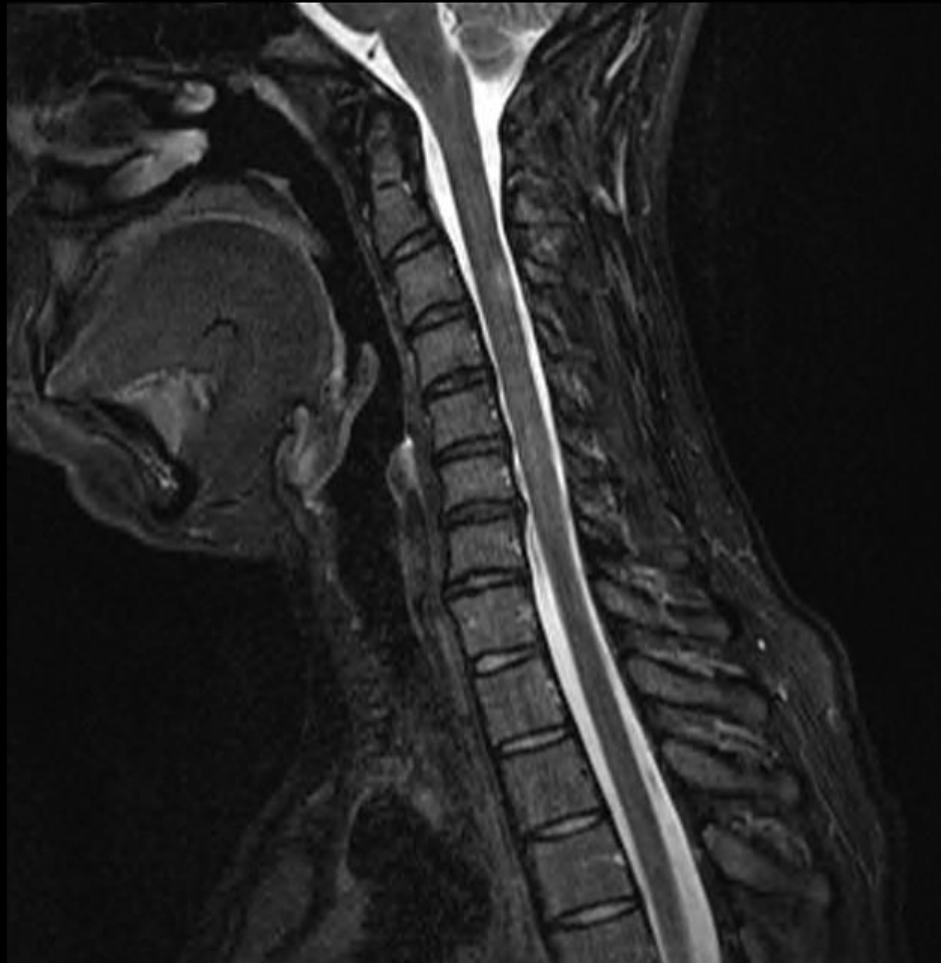26 yo police officer with facial pain

- ▶ 6 months severe lancinating left V2 V3 shooting pain with intermittent improvement
- ▶ 2 months of similar shoot pain (not simultaneous) on the right V2

Evaluation

- ▶ Examination is normal
- ▶ MRI negative
- ▶ LP negative
- ▶ Started oxcarbazepine 150mg bid

MRI s/p a work related MVA for neck pain

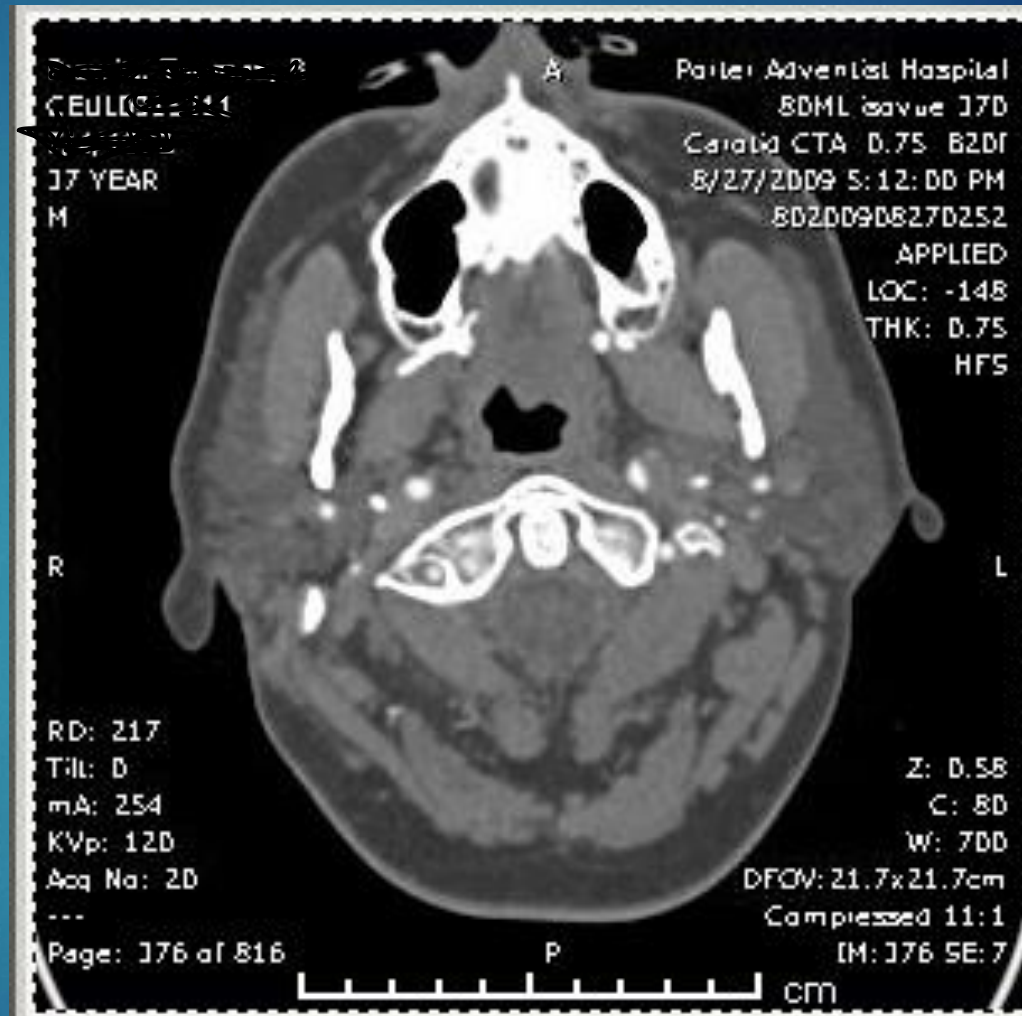

36 yo man with severe migraine with visual aura and slurred speech

- ▶ History of migraine
- ▶ Riding ATV without any event and had visual aura lasting 2 hours prior to bed
- ▶ Woke up with dysarthria and severe throbbing anterior/posterior headache on the left with photophobia

MRI

- ▶ Ptosis
- ▶ Dysarthria
- ▶ Left facial droop



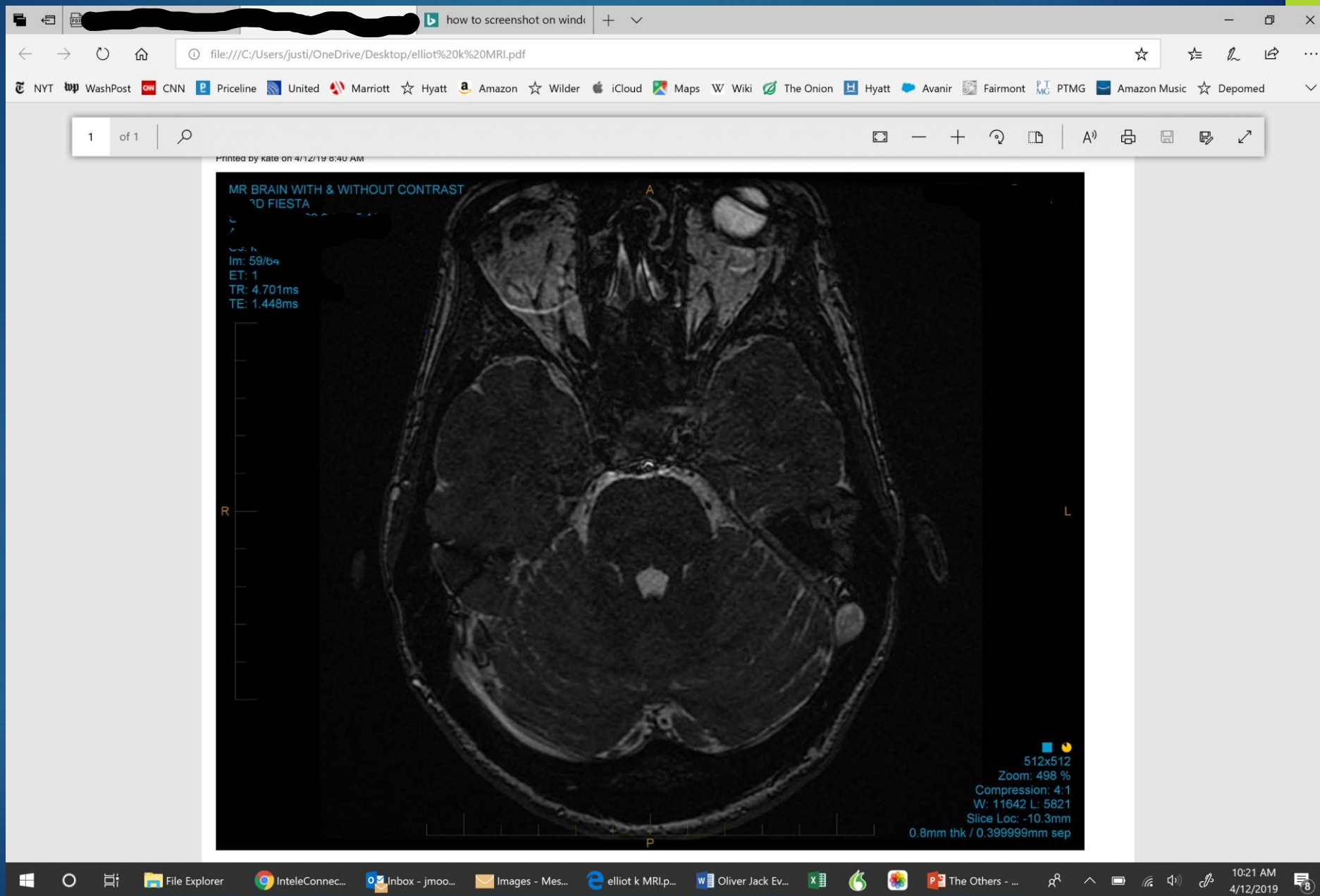
Hemicrania secondary to dissection

- ▶ Decreased severity with gabapentin
- ▶ Still with daily headaches

52 yo woman with occasional diplopia and pain behind the left eye

- ▶ Long history of “migraine” diagnosis
- ▶ Pain is persistent behind the left eye with pain radiating occasionally bilaterally
- ▶ Recurrent diplopia with a medial deviation of the left eye and mild exophthalmous

MRI



Tolosa hunt

- ▶ Granulomatous inflammation
- ▶ CN III, IV, VI paresis within 2 weeks of headache
- ▶ Steroids

47 yo women with migraine but a peculiar persistent pain in the temple


- ▶ Left temple pain does not move
- ▶ It is circular at 1.5cm width
- ▶ Decreased sensation in the region
- ▶ Not associated with occasional migraine pain

Nummular headache

- ▶ 1-6 cm
- ▶ Sharp contour
- ▶ Fixed shape
- ▶ Round or elliptical
- ▶ Mild-moderate pain with exacerbations
- ▶ 75% >3 months
- ▶ Not explained by skin abnormality



Treatment?




82 yo woman with 6 months new headache at 2am.

- ▶ Headache occurs nightly at 2am and persists until 6am
- ▶ No pain during the day
- ▶ Pain is stabbing but can be bilateral and worse with rest
- ▶ No associated symptoms

Next step?

- A. MRI
- B. Lithium
- C. Sign DNR Orders
- D. A and B



Hypnic Headache

- ▶ >50 yo
- ▶ 15-180min
- ▶ >3 months
- ▶ Wake up from sleep
- ▶ Bilateral > Unilateral


Some People Wake
Up Feeling Like a
Million Bucks.

<http://momslivingthrifty.com>

Me?

I wake up feeling like
"Insufficient Funds"

Headache is a different ball game.



Thank you

